
(877) 727-6800 www.antechimagingervices.com

Owner's Copy

PennHIP Report

Referring Veterinarian: Dr Kajsa Winbladh Email: kajsa.winbladh@blastjarnan.se	Clinic Name: Blue Star Animal Hospital Clinic Address: Gjutjärnsgatan 4 Göteborg, T 41707 Phone: Fax:(463) 123-7470
---	---

Patient Information

Client: Starke, Christian Patient Name: Jango Reg. Name: PennHIP Num: 188944 Species: Canine Date of Birth: 01 Nov 2021 Sex: Male Date of Study: 16 May 2023 Date of Report: 27 May 2023	Tattoo Num: Patient ID: 302087 Registration Num: Microchip Num: 643090000595356 Breed: SOUTH AFRICAN BOERBOEL MASTIFF Age: 18 months Weight: 119 lbs/54 kgs Date Submitted: 16 May 2023
--	--

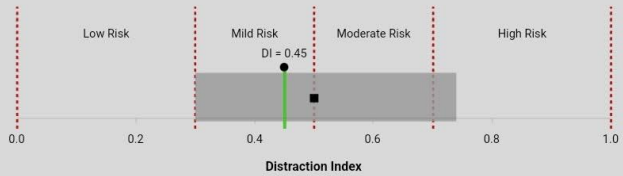
Findings

Distraction Index (DI): Right DI = 0.39, Left DI = 0.45.
Osteoarthritis (OA): **No radiographic evidence of OA for either hip.**
Cavitation/Other Findings: No cavitation present.

Interpretation

Distraction Index (DI): The laxity ranking is based on the hip with the greater laxity (larger DI). In this case the DI used is 0.45.
OA Risk Category: The DI is between 0.31 and 0.49. This patient is at mild risk for hip OA.
Distraction Index Chart:

SOUTH AFRICAN BOERBOEL MASTIFF



BREED STATISTICS: This interpretation is based on a cross-section of 1720 canine patients of the SOUTH AFRICAN BOERBOEL MASTIFF breed in the AIS PennHIP database. The gray strip represents the central 90% range of DIs (0.30 - 0.74) for the breed. The breed average DI is 0.50 (solid square). The patient DI is the solid circle (0.45).

SUMMARY: The degree of laxity (DI = 0.45) falls within the central 90% range of DIs for the breed. This amount of hip laxity places the hip at a mild risk to develop hip OA. **No radiographic evidence of OA for either hip.**